

EVALUATION OF CARDIO-PROTECTIVE ACTIVITY OF JATIPHALA (*MYRISTICA FRAGRANS* HOUTT.) IN WISTAR RATS

Dr. Manjunath H. Dundi*¹, Dr. Arun M. Chougale², Dr. Nayana K. Hashilkar³

¹PG Scholar, Department of Dravyaguna, KLEU's Shri BMK Ayurveda Mahavidyalaya,
Belgaum, Karnataka.

²Reader and H.O.D, Department of Dravyaguna, KLEU's Shri BMK Ayurveda
Mahavidyalaya, Belgaum, Karnataka.

³Associate Professor, Dept of Pharmacology, KLEU's J.N.Medical College, Belgaum,
Karnataka.

Article Received on
30 August 2017,

Revised on 20 Sept. 2017,
Accepted on 11 Oct. 2017

DOI: 10.20959/wjpr201713-9853

*Corresponding Author

Dr. Manjunath H. Dundi

PG Scholar, Department of
Dravyaguna, KLEU's Shri
BMK Ayurveda
Mahavidyalaya, Belgaum,
Karnataka.

ABSTRACT

Objective: To evaluate the cardioprotective activity of Jatiphala (*Myristica fragrans* Houtt.) in male wistar rats. Among cardiovascular disease, myocardial infarction is nowadays commonly found in all the age groups. Many treatment modalities are present to tackle with this condition, but despite of this there is high percentage of re-occurrence and also increase in the mortality rate due to Myocardial infarction. So keeping this point in consideration, an attempt is made to find a safer and cost effective drug which can be helpful in the prevention of Myocardial infarction in cardiovascular disease risk patients. Jaatiphala was chosen to test for its cardioprotective activity in the present study because in Bhavapraksha

nighantu we found its cardioprotective effect. **Materials and Methods:** Jatiphala churna was prepared using raw drug collected from natural habitat and after authentication by experts. Either sex wistar rats obtained from licensed breeder were divided into 3 groups- control group, ISO induced group and Pretreated group with Jatiphala churna. Control was given with normal water and food for 30 days, ISO group was also given with normal water and food for 30 days along with Inj. Isoproterenol on 29th and 30th day, Pretreated group was given with Jatiphala churna for 30 days along with Inj. Isoproterenol on 29th and 30th day. After completion of experiment rats were sacrificed and blood along with dissected heart was sent for serum estimation (SGOT, SGPT, CPK-MB and LIPID PROFILE) and Histo-

pathology studies. **Results:** Pretreated group with Jatiphala churna showed significant effect in case of SGOT, CPK-MB and CHOLESTROL when compared with the ISO treated group. Non-significant effect was observed in case of LDL, HDL, TRIGLYCERIDES and SGPT. **Conclusion:** The result of present study indicated that the prior administration of churna of *Myristica fragrans* Houtt. attenuates Isoproterenol induced MI.

KEY WORDS: *Jatiphala, Cardioprotective, Isoproterenol.*

INTRODUCTION

Myocardial infarction or acute myocardial infarction (AMI) is the medical term for an event commonly known as a heart attack. Myocardial infarction differs from cardiac arrest, although cardiac arrest can be a consequence of MI^[1]. According to WHO, an estimated 17.3 million people died from cardiovascular diseases in 2008. By 2030, almost 23.6 million people will die from CVD's as per the report published^[2]. Isoproterenol (ISO) is used as a model compound to induce infarct-like lesions in the rat and various other animal species. The lesions are most prevalent in areas of the heart that are most susceptible to ischemia^[3]. The current therapies to prevent or cure CVD'S are also not without adverse effects. Hence a safer, effective and economical drug should be used from natural sources. In Bhavaprakasha nigantu, Bhavamisra has mentioned Jatiphala under Karpuradi varga and said that this drug possess Hrudya action. Jatiphala acts as kapha-vatahara, shothahara, shwasahara, vedanasthapana, vrsya, sthambhaka^[4]. Recent researches suggest that Jatiphala has anti-inflammatory and anti-oxidant activity. Keeping these references as a base an attempt is made to evaluate cardioprotective effect of Jatiphala.

MATERIALS AND METHODS

Plant material: The fruits of Jatiphala (Nutmeg) were collected from Alapura region of Kerala, during *grishmaritu* as per classically mentioned. Jatiphala was authenticated by the expert at Central research facility, KLEU'S Shri BMK Ayurveda Mahavidyalaya.

Physico-chemical and Phyto-chemical analysis: Physico-chemical and Phyto-chemical analysis was done at Central research facility, KLEU'S Shri BMK Ayurveda Mahavidyalaya, Belgaum, Karnataka.

Preparation of churna: For medication, Jatiphala was prepared into Churna/powdered form (Sharangadhara Samhita)^[5]. Here Jatiphala churna was prepared by using pulverizer using sieve no. 120mesh in KLEU'S Ayurveda Pharmacy.

Animals

Either sex Wistar rats of 200-220 gms were used for the study. The animals were procured from JNMC animal house, Belgaum for experimental purpose. The animals were maintained under controlled conditions of temperature before the study. The animals were randomized into Control, ISO and Pretreated groups. The study conducted was approved by the Institutional Animal Ethical Committee IAEC (Reg.no. 25/369/2010AWD; Dated-05/11/2013).

Chemicals

Normal saline (0.9%), Isoproterenol Hydrochloride (Sigma- Aldrich Company, Product.code-I16504, quantity-500 mg).

Experimental Procedure

Rats in control group were just given normal water and food orally for 30days. Rats of disease control group were also given normal water and food orally for 30 days along with administration with Inj. Isoproterenol on 29th and 30th day at the dose of 85mg/kg body weight of rats with 0.6 ml normal saline^[10]. Rats of pretreated group were orally given with Jatiphala churna for 30days at a dose of 18mg/200gm body weight of rats.^[6] Along with administration of Inj. Isoproterenol on 29th and 30th day at the dose of 85mg/kg. Twenty four hours after the first Isoproterenol administration, all the rats were sacrificed and autopsied. The serum estimation and the histopathological examinations were done.

TABLE NO 1: DOSE AND TREATMENT ADOPTED^[7].

Group	Dose and route	Treated with
I Normal control	Orally	Normal water and food for 30 days
II Disease control	Orally, 0.6ml subcutaneously	Normal water and food for 30 days, Inj.Isoproterenol on 29 th and 30 th day
III Experimental drug	Orally, 0.6ml subcutaneously	Jatiphala churna for 30 days, Inj.isoproterenol on 29 th and 30 th day

Blood collection: Retro-orbital puncture by using capillary tube.

Organs /tissue collected: Heart (organs were kept in 10% formalin)

Parameters for Examination

1) **Gross examination of heart**^[8]: The dissected hearts were washed with ice cold saline. They were visually examined for inflammation, redness, scar formation, and color in all parts and grading was performed as follows.

Grade 0= No Lesion

Grade 1= Inflammation, redness, and capillary dilations.

Grade 2= Edema and yellowish ventricle portion

Grade 3= Atrium and ventricle turns yellow and scar formation

Grade 4= Diffuse heart, absolute scar formation, and increased necrosis portion

2) **Blood for biochemistry**^[9]: Serum enzyme estimation for- SGOT,SGPT,CK-MB, Serum lipid profile

3) **Histopathology study of heart tissue.**

4) **Heart and body weight ratio.**

Statistical analysis

All data will be expressed as Mean \pm Standard Deviation of the mean (SD). The data generated during the study was analyzed by one way anova test. $p < 0.05$ is considered to be significant. Graph pad Software (Version 6.02) is used for Statistical analysis.

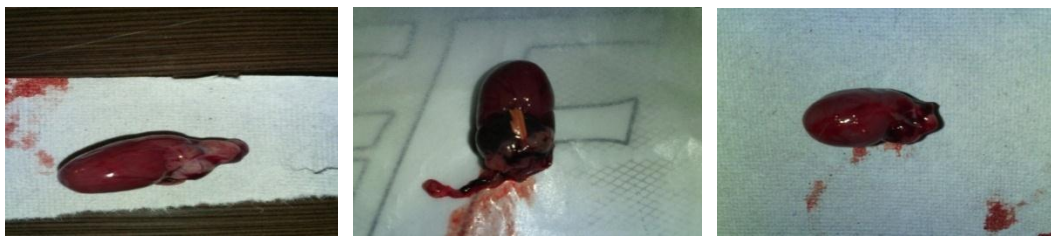RESULTS

Loss on drying, total ash, acid insoluble ash, pH, alcohol & water soluble extract were within std. limits [API]. Microbial load test was also within std. limits [IP].

Chemical constituents - Flavonoids, alkaloids, tannins, steroids, proteins, carbohydrates, reducing sugars, Calcium, Sodium, Chloride and Phosphate.

a. **Gross examination of heart**

The dissected hearts were washed with ice cold saline. They were visually examined for inflammation, redness and colour in all parts and grading was performed. The Isoproterenol (ISO) group showed marked inflammation, necrosis and diffused heart when compared with the normal control group. So it was graded as 4 (Photo.no.2). The Pretreated group showed reduction in edema, capillary dilation and with little redness and there was no necrosis found when compared with the Isoproterenol group. So it was graded as 3 (Photo.no.3).



1. Control group Heart

2. ISO group Heart

3. Pretreated group Heart

b. Heart weight/body weight ratio

Each rat was euthanized, weighed, and total body weight recorded. Removal of the heart was performed by dissecting the aortic root immediately above the aortic valves and the superior vena cava above the atria. The dry heart was weighed and recorded. Then, the heart was placed in fixative. The heart weight and body weight ratio was analyzed in all three groups. The Isoproterenol group showed marked increase in heart weight and body weight ratio due to hypertrophy when compared with the normal control group. The pretreated group with *Jatiphala churna* showed significant reduction in heart weight and heart/body weight ratio when compared with the isoproterenol group with p value less than 0.05. (Table.no.6)

c. Biochemical estimations

At the end of the experimental period, the blood samples were taken and serum was separated for analysis of different enzymes related to myocardial infarction. Estimation of elevated serum enzymes is a useful guide for necrosis of myocardium. CPK-MB has greater than 95% sensitivity and specificity for myocardial injury when measured between 24-36 hours. Isoproterenol causes significant damage to myocardium and endocardium and a significant increase in the level of serum marker enzymes such as SGOT, SGPT, CPK-MB and also increased lipid profile (increased CHOLESTEROL, TRIGLYCERIDES, LDL and decreased HDL). Rats treated with Isoproterenol showed a significant increase in activities of serum marker enzymes compared to normal rat group. Rats pretreated with *Jatiphala churna* showed a significant reduction in the Isoproterenol increased activities of SGOT, CPK-MB and CHOLESTROL. But statistically found to be non-significant in case of SGPT, HDL, TRIGLYCERIDES and LDL. (Table.no.6)

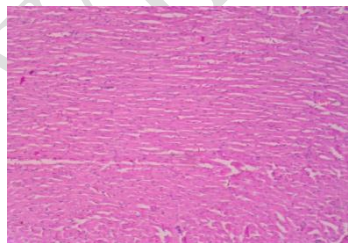
Table no 6: Mean \pm SD OF SGOT, SGPT, CPK-MB, CHOLESTROL, HDL, LDL and TRIGLYCERIDES and P value (Note: S- Significant and NS- Non-significant)

Parameters	A.Control Group Mean \pm SD	B.ISO Group Mean \pm SD	C.Pretreated Group Mean \pm SD	P Value Between B & C At 95%
SGOT	106.3 \pm 51.17	435.0 \pm 185.7	280.5 \pm 155.9	0.0059**
SGPT	57.33 \pm 19.03	226.8 \pm 45.35	193.2 \pm 90.97	0.6544 (NS)
CPK-MB	219.3 \pm 50.38	1305 \pm 51.82	620.7 \pm 84.41	< 0.0001****
CHOLESTROL	50.67 \pm 13.75	73.17 \pm 8.954	57.67 \pm 14.09	0.0438*
HDL	17.67 \pm 1.366	14.83 \pm 1.472	16.17 \pm 1.169	0.3867(NS)
LDL	17.50 \pm 1.517	32.00 \pm 6.164	25.33 \pm 6.408	0.1762(NS)
TRIGLYCERIDES	139.5 \pm 26.17	234.5 \pm 62.79	166.5 \pm 57.39	0.1668(NS)
H/Bwt. Ratio	3.867 \pm 0.5828	5.525 \pm 0.3127	4.442 \pm 0.8071	0.0176*

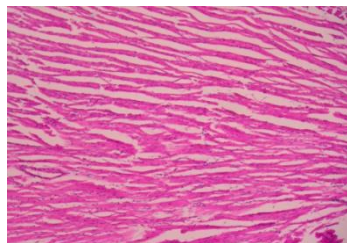
d. Histopathological study (Microscopic)

At the end of the study, the heart was isolated and washed with ice cold saline. The tissue was fixed in 10% buffered neutral formalin solution. After fixation, tissues were embedded in paraffin-wax and five micrometer thick sections were cut and stained with hematoxylin and eosin. The slides were observed under light microscope and photomicrograph was taken.

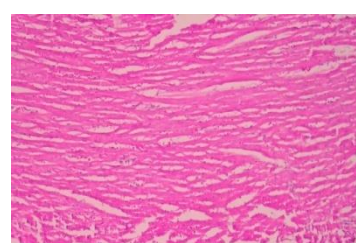
Photomicrograph of rat heart of the normal control group showed the endocardium, myocardium and epicardium as well as papillary muscles and vasculature which were all normal and healthy. There was no muscular hypertrophy or evidence of myositis (necrosis or round cell infiltrates) (Photo.no.4). Isoproterenol treated group shows focal myonecrosis with myophagocytosis and lymphocytic infiltration. Vacuolar changes and prominent oedema along with chronic inflammatory cells are visible (Photo.no.5). Rats pretreated with Jatiphala churna showed lesser degree of myonecrosis, myophagocytosis and lymphocytic infiltration, oedema and very little infiltration of inflammatory cells(Photo.no.6).



4.HP of normal group(10x)



5.HP of ISO group(10x)



6.HP of pretreated group(10x)

DISCUSSION

Acute myocardial infarction, which rises out of a lot risk factors working in concert, gives rise to a lot of unfavourable biochemical outcomes^[10]. Isoproterenol, a potent synthetic

catecholamine, induces sub-endocardial myocardial ischemia, hypoxia and finally fibroblastic hyperplasia with decreased myocardial compliance which closely resembles local myocardial infarction-like pathological changes seen in human myocardial infarction^[11]. Hence for the present study Isoproterenol induced myocardial infarction model was used to evaluate cardioprotective activity of Jatiphala.

On gross examination of heart the Isoproterenol (ISO) group showed marked inflammation, scar formation, and diffused heart when compared with the normal control group [Photo.no.2]. The Pretreated group showed reduction in edema, capillary dilation and with little redness when compared with the Isoproterenol group [Photo.no.3]. The heart weight and body weight ratio was analyzed in all three groups. The pretreated group with Jatiphala churna showed reduction in heart weight and heart/body weight ratio when compared with the Isoproterenol group.

Rats treated with Isoproterenol showed significant increase ($p < 0.05$) in activities of serum marker enzymes compared to normal rat group. Rats pretreated with Jatiphala churna showed significant reduction in the Isoproterenol increased activities of SGOT, CPK-MB, CHOLESTROL but statistically non-significant in SGPT, HDL, TRIGLYCERIDES, and LDL. Pretreatment with Jatiphala churna to rats for 30 days, followed by ISO subcutaneous injection on the 29th and 30th days, showed significant ($p < 0.05$) reduction in the ISO-induced increased activities of CPK. In the present study, there is significant decrease in the values of CPK-MB of pretreated group when compared with ISO treated group. This suggests that Jatiphala churna prevents or decreases release CK in serum.

Photomicrograph of rat heart of the normal control group showed the endocardium, myocardium and epicardium as well as papillary muscles and vasculature which were all normal and healthy. There was no muscular hypertrophy or evidence of myositis (necrosis or round cell infiltrates) [Photo.no.4]. Isoproterenol treated group shows focal myonecrosis with myophagocytosis and lymphocytic infiltration. Vacuolar changes and prominent oedema along with chronic inflammatory cells are visible [Photo.no.5]. Rats pretreated with aqueous extract of Jatiphala churna showed lesser degree of myonecrosis, myophagocytosis and lymphocytic infiltration, oedema and very little infiltration of inflammatory cells which shows that Jatiphala has cardioprotective effect [Photo.no.6].

Flavonoids are found present in the fruits of jatiphala. Flavonoids are important components having beneficial effects on the cardio-vascular function, mainly due to their anti-oxidant activity. Recent evidence indicated that they exert cardio-protective effects against myocardial ischaemic injury^[12]. This can be taken into consideration which resulted in the increased anti-oxidant level in myocardium of pre-treated group which resulted in the prevention of further injury.

In present study there is reduction of inflammation seen in histopathology reports of pretreated group. As it also has hepato-protective effect, it helped out in the reduction of SGOT, SGPT and Lipid profile (decreased LDL, CHOLESTEROL, TRIGLYCERIDES and increased HDL). Myristicin, a terpenoid is present in Jatiphala which is known to possess analgesic, anti-inflammatory, hepato-protective properties^[13].

So it can be taken into consideration that due to its anti-inflammatory, anti-oxidant, Hepatoprotective, anti-hyperlipidemic and membrane stabilizing effect, Jatiphala can combat Myocardial infarction.

CONCLUSION

The result of present study indicated that the prior administration of Jatiphala Churna (*Myristica Fragrans* Houtt.) attenuates Isoproterenol induced MI. Pre-treated group with Jatiphala churna showed significant effect in case of SGOT, CPK-MB, CHOLESTROL and Heart & Body weight ratio, when compared with the ISO treated group. Non-significant effect was observed in case of LDL, HDL, TRIGLCERIDES and SGPT. The cardioprotective activity of *Myristica Fragrans* Houtt. is probably related to its anti-inflammatory, anti-oxidant, anti-hyperlipidemic activity, Hepatoprotective activity and also its ability to strengthen the myocardial membrane by its membrane stabilizing action. Even though the biochemical & histopathological parameters show efficacy of jatiphala on cardio-protectivity, this cannot prevent death of the animals.

REFERENCES

1. Available from: URL:http://en.wikipedia.org/wiki/Myocardial_infarction Date: 20/12/14
2. Global atlas on Cardiovascular disease prevention and control, WHO- 2013 URL: http://www.who.int/cardiovascular_diseases/en/
3. Jun Zhang, Alan Knapton, Steven E. Lipshultz, James L. Weaver and Eugene H. Herman, Isoproterenol-induced Cardiotoxicity in Sprague-Dawley Rats: Correlation of Reversible

- and Irreversible Myocardial Injury with Release of Cardiac Troponin T and Roles of iNOS in Myocardial Injury, doi: 1080/01926230701389316, *Toxicol Pathol*, June 2007; 35(4): 606-617
4. Bhavamishra, edited by Prof.Chunekar KC, Dr.Pandey GS. Bhavaprakasha nighantu.Varanasi: Chaukhambha Bharathi Academy; 2004; 206. (Karpuradi Varga).
 5. AcharyaSharangadhara. Edited by PanditParashuramShastriVaidyasagar. “SharangadharaSamhita” with the commentary Adhamalla’sDeepika and Kashirama’s Gudārtha Deepika. Madhyama khanda, Chapter no. 6. Shloka no.1st. 5th ed. Varanasi: ChaukhambhaOrientalia; 2012; 152.
 6. Murugesan Madhesh, Ramalingam Revathi and Vaiyapuri Manju, Cardioprotective effect of fenugreek on Isoproterenol-induced myocardial infarction in rats, *Indian Journal Pharmacol*, 2011 Sep-Oct; 43(5): 516–519.
 7. The Ayurvedic Pharmacopoeia of India” Vol IV, 1st edition published by the controller of publications civil lines, Delhi -110054, 2009; 62-3.
 8. Neha Kesarwani and Lubna azmi, Evaluation of cardioprotective effect of *Tinospora cordifolia* against isoprenaline induced myocardial infarction in rats, *International journal of current microbiology and applied sciences*,ISSN: 2319-7706 2014; 3(3): 543-555.
 9. Saravanan P, Davidson NC, Schmidt EB, Calder PC, Cardiovascular effects of marine omega-3 fatty acids, PMID:20638121, 2011 Apr 16; 377(9774): 1318.
 10. Farogh Ahsan, H.H. Siddiqui, Tarique Mahmood, Ritesh Kumar Srivastav, Ahmad Nayeem, Evaluation of Cardioprotective effect of *Coleus forskohlii* against Isoprenaline induced myocardial infarction in rats, *Indian Journal of Pharmaceutical and Biological Research*, 2014; 2(1): 17-25.
 11. Rona, G., Chappel, CI., Kahn, DS. Isoproterenol induced cardiac necrosis. *Ann. NY. Acad. Sci.*, 1969; 156(1): 285- 293.
 12. Testai L, Martelli A, Cristofaro M, Breschi MC, Calderone V, Cardioprotective effects of different flavonoids against myocardial ischaemia/reperfusion injury in Langendorff-perfused rat hearts, 2013 May; 65(5): doi: 10.1111/jphp.12032, Epub 2013 Feb 26, PMID: 23600393, 750-6.
 13. P G Latha, P G Sindhu, S R Suja, B S Geetha, P Pushpangadan & S Rajasekharan, Pharmacology and chemistry of *Myristica fragrans* Houtt. a review. *Journal of Spices and Aromatic Crops*, 2005; 14(2): 94–101.